

Can Cervical Arthroplasty Impact Alignment? A Comparison of the Synergy Disc with Cervical Fusion

Kemal Yucesoy¹, Kasim Z Yuksel^{2*}, Idiris Altun², Murvet Yuksel³ and Orhan Kalemci⁴

¹Department of Neurosurgery, Dokuz Eylul University, Izmir, Turkey

²Department of Neurosurgery, Kahramanmaraş Sutcu Imam University, Kahramanmaraş, Turkey

³Department of Radiology, Kahramanmaraş Sutcu Imam University, Kahramanmaraş, Turkey

*Corresponding author: Kasim Z Yuksel, Faculty of Medicine, Department of Neurosurgery, Kahramanmaraş Sutcu Imam University, Kahramanmaraş, Turkey, Tel: +905053718218; E-mail: kasim.z.yuksel@gmail.com

Rec Date: December 06, 2017; Acc Date: December 12, 2017; Pub Date: December 16, 2017

Copyright: © 2017 Yuksel KZ, et al. This is an open-access article distributed under the terms of the Creative Commons Attribution License, which permits unrestricted use, distribution, and reproduction in any medium, provided the original author and source are credited.

Abstract

Background context: Synergy disc is a new cervical disc prosthesis that incorporates alignment restoration while providing full intervertebral disc kinematics.

Purpose: This follow-up study with 40 Synergy Disc patients with 24-month follow-up compared cervical alignment changes with a retrospective cohort of 30 single level anterior cervical discectomy and fusion (ACDF) patients.

Study design/setting: The pilot trial was a multi-center, prospective, consecutive patient enrollment study using the Synergy Disc for the treatment of single and two-level degenerative disc disease of the cervical spine.

Patient sample: The procedure was performed on 43 patients (45 implants) with follow-up on 40 patients (42 implants). For the historical cohort ACDF arm, 30 patients with similar follow-up with single level anterior discectomy, fusion and plating were used for segmental lordosis measurements.

Outcome measures: For the Synergy Disc group, the kinematic parameters included: range of motion (ROM), shell angle (SA), disc height (DH), sagittal plane translation and center of rotation (COR) in the X and Y direction. Standard assessments of clinical outcomes were also measured (Neck Disability Index, Visual Analog Scale). For the fusion arm, only functional spinal unit (FSU) angle was recorded using a single pre-operative and post-operative standing lateral cervical radiograph.

Methods: In the Synergy Disc group, static and dynamic radiological assessments were performed in 43 consecutive patients prior to the placement of the Synergy Disc. Forty patients were studied for the course of the study protocol (3 patients lost to follow-up). For the Synergy Disc group, all kinematic parameters were examined at a minimum of 24 months follow-up. Neck Disability Index and Visual Analog Scale for arm and neck pain were collected and analyzed. For the fusion group, standing lateral radiographs were reviewed.

Results: At a mean of 28 months with all patients having a minimum of 24-month follow-up (40 patients, 42 implants), the average SA of the Synergy Disc was maintained at $6 \pm 2.7^\circ$ of lordosis. There was significant improvement in all clinical outcome measures. In the fusion group, with a similar follow-up period, there was a 4° increase in lordosis of the FSU.

Conclusion: The Synergy Disc had an endplate angle of $6 \pm 2.7^\circ$ at 2 years following surgery. This was comparable to the lordotic correction provided by an anterior cervical discectomy with interbody fusion and plating.

Keywords: Sagittal balance; Kyphosis; Cervical arthroplasty; Cervical sagittal alignment; Synergy Disc; Kinematics; Center of rotation; Artificial disc

Introduction

Degeneration of the cervical disc can result in loss of disc height, resulting in disc space narrowing and collapse [1]. In symptomatic, degenerated segments with parallel or kyphotic vertebral endplates, the

goal of reconstruction of the disc space after decompression incorporates a strategy to recreate segmental cervical lordosis [2].

Adjacent segment disease (ASD), which is a suspected consequence of anterior cervical discectomy and fusion (ACDF), can be potentially delayed by preserving disc space kinematics of the functional spinal unit with cervical arthroplasty [3,4]. The Synergy Disc, a new cervical disc replacement, has been designed to create or preserve segmental lordosis following discectomy. Early theoretical and clinical experience suggests it has alignment advantages over existing cervical disc replacements [5,6]. The goal of the present study was to report the 2-

year results of the Synergy cohort and to determine if it can provide a sagittal alignment correction comparable to the gold standard of ACDF.

Materials and Methods

Patient population

Inclusion and exclusion criteria were used to identify 43 consecutive patients with refractory radiculopathy and/or myelopathy requiring surgical intervention. Patients were prospectively enrolled in a pilot safety study with Synergy Disc, after approval from the Research Ethics Board at Dokuz Eylul University. In all cases, a standard right-sided cervical approach was undertaken to perform an anterior cervical discectomy (ACD), with excision of the posterior longitudinal ligament, followed by implantation of the Synergy Cervical Disc prosthesis. Patients were positioned supine with the neck in neutral alignment for the surgery and a 6° lordotic implant with a 5mm height were used in all cases.

Patient selection criteria

Exclusion criteria included previous cervical spine surgery, trauma, active infection, osteoporosis, multilevel spondylotic disc degeneration and radiographic signs of instability. Pre-operative radiographs recorded ten patients with pre-operative straightening of the cervical spine, while eight patients had a reducible kyphosis. The remaining 22 patients demonstrated a pre-operative cervical lordosis.

For the retrospective fusion arm, 14 patients had a normal pre-operative lordosis, 10 had pre-operative straightening of the cervical spine, and 6 had focal kyphosis at the surgical level.

Clinical evaluation

Synergy Disc patients completed visual analog scale (VAS) for arm and neck pain and the Neck Disability Index (NDI) questionnaires in order to measure disease specific and overall well-being outcomes. Questionnaires were administered pre-operatively and at 1.5, 3, 6, 12 and at 24-months post-operatively.

Radiographic analysis

Medical Metrics, Inc., Houston, TX provided independent prospective x-ray analysis of cervical spine radiographs. Upright neutral, flexion and extension cervical x-rays were obtained before surgery and at regular post-operative time points. Quantitative Motion Analysis (QMA) software was used to analyze the kinematics at the surgical level(s) [7]. The kinematic parameters that were examined included disc height (DH), sagittal plane translation, ROM, shell angle (SA) and center of rotation (COR) in the X and Y direction.

For the fusion arm, the FSU was retrospectively calculated by an independent observer on 3 separate occasions for each radiograph and averaged to ensure accurate measurement of the FSU angle.

Synergy disc description

Synergy Disc is a 3-piece design that has either 0° or 6° of lordosis incorporated into a 5 or 6 mm height MRI compatible prosthesis. The sagittal and coronal alignment control is incorporated into the polyethylene. The prosthesis allows for a mobile COR, with fully coupled ROM.

Statistical analysis

Mean values and standard deviations (represented after ±) were determined for DH, ROM, translation, SA and COR X and Y. A two-tailed Student's t-test with an alpha level set at 0.05 was used. A paired t-test was further used to assess measure differences between pre-and post-operative VAS and NDI scores.

Results

Synergy disc group

Patient population: Forty patients (38 patients with 1-level and 2 patients with 2-level) met the minimum requirement of 24 months post-operative follow-up. The mean age was 45.8 years (18 females and 22 males). All device sizes were used (medium 47%; small 35% and large 18%). There were no device or instrument related complications. No delayed device complications, such as subsidence and migration, were demonstrated on imaging and clinical follow-up.

Clinical outcomes: VAS neck pain score improved statistically at the last follow-up (8.9 ± 1.0 pre-operatively vs. 0.5 ± 0.5 post-operatively, $p < 0.05$). Arm pain VAS scores also improved (8.3 ± 0.6 pre-operatively vs. 0.9 post-operatively, $p < 0.05$). Over the 24-month period, mean NDI scores changed significantly (4.1 ± 0.8 pre-operatively vs. 1.3 ± 0.2 post-operatively, $p < 0.05$).

Radiographic outcomes: The mean pre-operative disc angle (DA) was $4.28 \pm 5.45^\circ$. In all cases, a 6° lordotic core was inserted into the device. At 24 months the average SA of the Synergy Disc was $6 \pm 2.7^\circ$ of lordosis, demonstrating a significant increase in lordosis at the index level $p = 0.007$ (Figure 1).

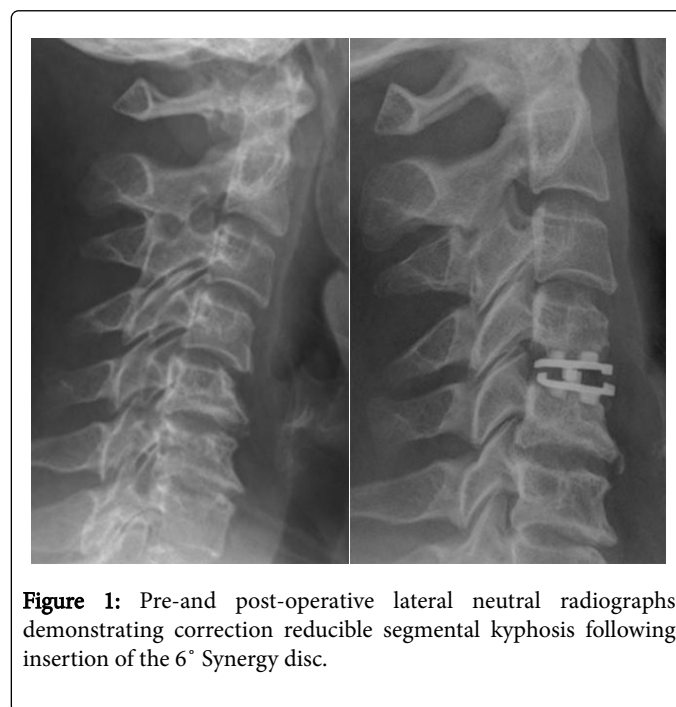


Figure 1: Pre-and post-operative lateral neutral radiographs demonstrating correction reducible segmental kyphosis following insertion of the 6° Synergy disc.

ROM at the surgical level at 24 months post-operatively was unchanged ($11 \pm 5.2^\circ$ pre-operatively vs. $9.7 \pm 4.2^\circ$ post-operatively; $p > 0.05$; Figure 2). The mean DH increased significantly (3.8 ± 0.8 mm pre-operatively vs. 4.9 ± 1.0 mm post-operatively, $p < 0.05$). Sagittal

plane translation did not change (1.7 ± 1.0 mm pre-operatively vs. 1.6 ± 1.2 mm post-operatively, $p > 0.05$).

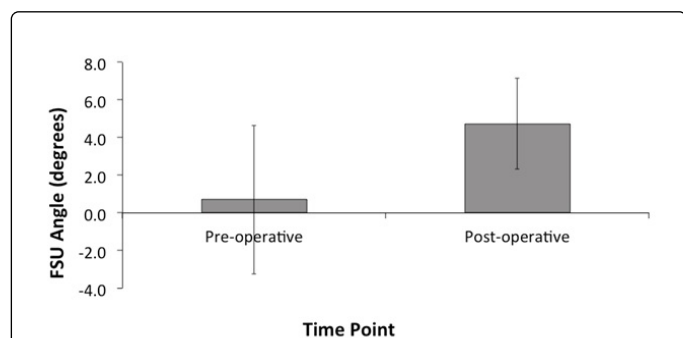


Figure 2: In the ACDF group, the pre-operative Functional Spinal Unit (FSU) angle measurement at the index level was $0.71 \pm 3.95^\circ$. At the FSU angle increased to $4.74 \pm 2.42^\circ$, representing a significant increase in lordosis at the surgical level, $p < 0.05$. Error bars represent standard deviation.

COR X remained unchanged (-0.9 ± 0.9 mm pre-operatively vs. -0.3 ± 0.7 mm post-operatively, $p > 0.05$). A shift superiorly occurred in COR Y (3.9 ± 2.1 mm pre-operatively vs. 2.3 ± 2.4 mm post-operatively; $p < 0.05$).

Fusion group

Thirty patients with single level ACDF were retrospectively reviewed for FSU angle measurements pre-and a mean of 19 months post ACDF. The pre-operative FSU angle measurement at the index level was $0.71 \pm 3.95^\circ$. Following surgery, the FSU angle increased to $4.74 \pm 2.42^\circ$, representing a significant increase in lordosis at the surgical level, $p < 0.05$ (Figure 2). Post-operatively, 27 patients demonstrated lordosis at the surgical level, with only 3 cases of a parallel configuration at the surgical level.

Discussion

The 6° Synergy Disc provided $6 \pm 2.7^\circ$ of lordosis to the surgical level in all patients. To relate the lordosis correction of the disc replacement with the gold standard (ACDF), we retrospectively collected 30 ACDF cases with comparable follow-up and analyzed the FSU for this retrospective series of fusion cases. The FSU angle for fusion patients was $0.71 \pm 3.95^\circ$ pre-operatively and $4.74 \pm 2.42^\circ$ at last follow-up, representing a significant improvement in segmental lordosis. Following cervical discectomy, both the Synergy Disc and traditional fusion provided segmental alignment restoration.

Increasingly, cervical disc replacement has been found to have an unpredictable impact in segmental alignment [8-15]. In two case series, Pickett et al. reported a loss segmental lordosis as high 49% of inserted Bryan artificial discs ($n=96$) [8,16]. Similar results have been demonstrated by other groups, with Kim et al. demonstrating only 36% of patients with a pre-operative lordotic alignment were able to maintain lordosis following surgery [15]. The literature regarding cervical fusion have reported the development of neck pain and accelerated ASD related to segmental kyphosis at the surgical level [2,17]. There is no current literature confirming a relationship between segmental alignment and neck pain in cervical arthroplasty pain. In

our prospective series with the lordotic Synergy Disc, neck pain was negligible as demonstrated by the VAS neck pain scores [17].

Engineering and surgical nuances can alter endplate configuration with the current ball and socket cervical disc replacements [18,19]. Factors such as intraoperative positioning, asymmetry of vertebral endplates, angle of prosthesis insertion and a pre-existing straight or kyphotic segmental alignment have been implicated in the post-operative endplate alignment of ball and socket prosthesis [10,15,20]. In a retrospective cohort of 259 patients, neck pain was more common in the arthroplasty group at 15.8% ($n=27$ patients) when compared to the fusion group at 12.5% ($n=11$ patients) [21]. Although some authors have suggested that ball and socket can provide a modest increase in alignment, Rabin et al. demonstrated that a lordotic configuration of ProDisc-C endplates was associated with restricted motion from neutral to extension [5,22-24]. Similarly, Du et al. described that even with a ball and socket design that incorporated 7° of lordosis in endplates (Discover Cervical Disc, DePuy Spine, Raynham MA, USA), there were reported cases of device endplate kyphosis [25].

In a study by Harrison et al. the average segmental cervical lordosis in 252 asymptomatic subjects was between 6 and 7 degrees [14]. Degenerative disc disease, however, results in collapse of the disc space, with resulting changes in cervical alignment [2,7,8]. In patients with degenerative discs having surgery, the average pre-operative disc angle was reported be -0.7° ($n=47$ patients) [9]. Another series found that 40% of patients undergoing surgery had pre-operative angles between $1-2^\circ$ lordosis and 30% were straight (parallel with 0°) [10]. Loss of anterior DH has been implicated most important indicator predicting change in the disc space angle [11]. In a cohort of 242 patient, 43% of patients demonstrated a kyphotic angulation while 22% of patients had a straight spine. Because patients in our series had a pre-operative FSU angle of $0.71 \pm 3.95^\circ$, traditional fusion techniques, including lordotic allografts and plates, were used to restore cervical alignment [2,12,13]. In our fusion cohort, the FSU angle increased significantly to $4.74 \pm 2.42^\circ$. For the Synergy group, the mean post-operative SA demonstrated $6 \pm 2.7^\circ$ of lordosis. Hence, both ACDF and the Synergy Disc restored DH an increase in lordosis at the surgical level [26].

Patient selection has continued to evolve since the early experience with cervical disc replacement. Juhl et al. found only 60% of asymptomatic volunteers had a lordotic spine, while 19% and 21% had either a straight or kyphotic curvature, respectively. With reported cases of endplate kyphosis, patients with straight or kyphotic spinal alignment have been a relative contra-indication for disc replacement. Selection of our disc replacement group demonstrated this bias, with the mean pre-operative DA being $4.28 \pm 5.45^\circ$ while the preoperative FSU angle for the fusion group was $0.71 \pm 3.95^\circ$. Given this bias, direct comparison of the groups was impossible. In our patient cohort, the Synergy Disc did provide alignment restoration in patients with straight or kyphotic cervical alignment (Figure 1) [27].

Study Limitations

The goal of this pilot study was to indirectly compare alignment changes between ACDF and cervical arthroplasty (Synergy Disc). Although the Synergy cohort was prospectively collected, it was compared to retrospective fusion data, precluding a direct statistical comparison. This study was not designed to randomize patients into either disc replacement or fusion. The sample size was limited and the duration of follow-up relatively short (24 months) to assess the impact on adjacent segment changes.

Conclusion

Studies utilizing imaging analysis are typically limited by patient factors including body habitus, out of plane motion, patient effort and variability in radiographic techniques. Because fusion prevented the assessment of endplate angle, the FSU angle was calculated for the fusion patients while the more accurate assessment of SA was made for the cervical arthroplasty group. This study addresses only sagittal plane ROM and did not assess axial rotation or lateral bending. Finally, a 24 months follow-up period was based on results by Ryu et al. which found no change in SA 12 months following surgery [28]. Ideally, longer-term follow-up is needed to address the durability of sagittal alignment correction by a disc replacement.

This pilot study demonstrated that traditional fusion and Synergy Disc restored and maintained segmental alignment after anterior cervical discectomy.

References

1. Rechtman AM, Borden AGB, Gershon-Cohen J (1961) The lordotic curve of the cervical spine. *Clinical Orthopaedics* 20: 208-216.
2. Katsuura A, Hukuda S, Saruhashi Y, Mori K (2001) Kyphotic malalignment after anterior cervical fusion is one of the factors promoting the degenerative process in adjacent intervertebral levels. *Eur Spine J* 10: 320-324.
3. Pickett GE, Rouleau JP, Duggal N (2005) Kinematic analysis of the cervical spine following implantation of an artificial cervical disc. *Spine* 30: 1949-1954.
4. Mummaneni PV, Robinson JC, Haid RW (2007) Cervical arthroplasty with the Prestige LP cervical disc. *Neurosurgery* 60: 310-314.
5. Lazaro BC, Yucesoy K, Yuksel KZ (2010) Effect of arthroplasty design on cervical spine kinematics: analysis of the Bryan Disc, ProDisc-C, and Synergy Disc. *Neurosurgical Focus* 28: E6.
6. Crawford NR, Arnett JD, Butters JA (2010) Biomechanics of a posture-controlling cervical artificial disc: mechanical, in vitro, and finite-element analysis. *Neurosurgical focus* 28: E11.
7. Katsuura A, Hukuda S, Imanaka T, Miyamoto K, Kanemoto M (1996) Anterior cervical plate used in degenerative disease can maintain cervical lordosis. *J Spinal Disord* 9: 470-476.
8. Pickett GE, Mitsis DK, Sekhon LH, Sears WR, Duggal N (2004) Effects of a cervical disc prosthesis on segmental and cervical spine alignment. *Neurosurgical focus* 17: E5.
9. Shim CS, Lee SH, Park HJ, Kang HS, Hwang JH (2006) Early clinical and radiologic outcomes of cervical arthroplasty with Bryan Cervical Disc prosthesis. *J Spinal Disord Tech* 19: 465-470.
10. Fong SY, DuPlessis SJ, Casha S, Hurlbert RJ (2006) Design limitations of Bryan disc arthroplasty. *Spine J* 6: 233-241.
11. Johnson JP, Laurysen C, Cambron HO (2004) Sagittal alignment and the Bryan cervical artificial disc. *Neurosurgical focus* 17: E14.
12. Takeshima T, Omokawa S, Takaoka T, Araki M, Ueda Y, et al. (2002) Sagittal alignment of cervical flexion and extension: Lateral radiographic analysis. *Spine* 27: 348-355.
13. Rajshekhar V, Arunkumar MJ, Kumar SS (2003) Changes in cervical spine curvature after uninstrumented one- and two-level corpectomy in patients with spondylotic myelopathy. *Neurosurgery* 52: 799-804.
14. Harrison DD, Harrison DE, Janik TJ, Cailliet R, Ferrantelli JR, et al. (2004) Modeling of the sagittal cervical spine as a method to discriminate hypolordosis: results of elliptical and circular modeling in 72 asymptomatic subjects, 52 acute neck pain subjects, and 70 chronic neck pain subjects. *Spine* 29: 2485-2492.
15. Kim SW, Shin JH, Arbatin JJ, Park MS, Chung YK, et al. (2008) Effects of a cervical disc prosthesis on maintaining sagittal alignment of the functional spinal unit and overall sagittal balance of the cervical spine. *Eur Spine J* 17: 20-29.
16. Pickett GE, Sekhon LH, Sears WR, Duggal N (2006) Complications with cervical arthroplasty. *J Neurosurg Spine* 4: 98-105.
17. Kawakami M, Tamaki T, Yoshida M, Hayashi N, Ando M, et al. (1999) Axial symptoms and cervical alignments after cervical anterior spinal fusion for patients with cervical myelopathy. *Journal of Spinal Disorders* 12: 50-56.
18. Sears WR, Sekhon LH, Duggal N, Williamson OD (2007) Segmental malalignment with the Bryan Cervical Disc prosthesis--Does it occur? *J Spinal Disord Tech* 20: 1-6.
19. Sears WR, Duggal N, Sekhon LH, Williamson OD (2007) Segmental malalignment with the Bryan cervical disc prosthesis--contributing factors. *J Spinal Disord Tech* 20: 111-117.
20. Yoon DH, Yi S, Shin HC, Kim KN, Kim SH (2006) Clinical and radiological results following cervical arthroplasty. *Acta neurochirurgica* 148: 943-950.
21. Tracey RW, Kang DG, Cody JP, Wagner SC, Rosner MK, et al. (2014) Outcomes of single-level cervical disc arthroplasty versus anterior cervical discectomy and fusion. *J Clin Neurosci* 21: 1905-1908.
22. Anakwenze OA, Auerbach JD, Milby AH, Lonner BS, Balderston RA (2009) Sagittal cervical alignment after cervical disc arthroplasty and anterior cervical discectomy and fusion: results of a prospective, randomized, controlled trial. *Spine* 34: 2001-2007.
23. Ahn PG, Kim KN, Moon SW, Kim KS (2009) Changes in cervical range of motion and sagittal alignment in early and late phases after total disc replacement: radiographic follow-up exceeding 2 years. *J Neurosurg Spine* 11: 688-695.
24. Rabin D, Bertagnoli R, Wharton N, Pickett GE, Duggal N (2009) Sagittal balance influences range of motion: An in vivo study with the ProDisc-C. *Spine J* 9: 128-133.
25. Du J, Li M, Liu H, Meng H, He Q, et al. (2011) Early follow-up outcomes after treatment of degenerative disc disease with the discover cervical disc prosthesis. *Spine J* 11: 281-289.
26. Garcia M, Tzermiananos M, Voronov L, Cahill P, Rinella A, et al. (2006) Effect of cervical disc prosthesis height on kinematics and foraminal size. *Spine J* 6: 72S-73S.
27. Juhl JH, Miller SM, Roberts GW (1962) Roentgenographic variations in the normal cervical spine I. *Radiology* 78: 591-597.
28. Ryu WH, Kowalczyk I, Duggal N (2013) Long-term kinematic analysis of cervical spine after single-level implantation of Bryan cervical disc prosthesis. *Spine J* 13: 628-634.